

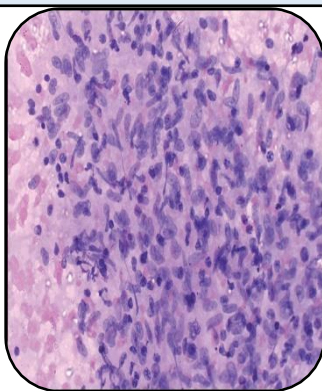
<b>Patient Name</b>	MR. MANOJ YADAV	<b>Client Name</b>	Life Safe Pathology Lab,	<b>Specimen Received</b>	03/07/17
<b>Age/Sex</b>	25/M		Rewari	<b>Specimen Type</b>	Tissue
<b>Patient ID</b>	011707030136	<b>Client Code</b>	MolQ1102CM	<b>Collection Date</b>	03/07/17
<b>Specimen ID</b>	MOLQ/B-488/17	<b>Ref. Doctor</b>		<b>Report Date</b>	07/07/17

## SURGICAL PATHOLOGY REPORT

**Suggestive of reactive lymphadenitis , Left Axillary Lymphnode.**

### DIAGNOSIS

**SUGGESTIVE OF REACTIVE LYMPHADENITIS.**



### SPECIMEN

Left Axillary Lymphnode.

### GROSS

1) Received multiple 1x1cm greyish white tissue piece.

### Microscopy

- 1) Section examined shows mild effacement of architecture of Lymphnode, fibrocollagenous capsule with blood vessels and few lymphoid follicles having small lymphocytes, centrocytes and histiocytes.
- 2) No granuloma seen in sample received.

**Note :** All biopsy specimen will be stored for 15 (fifteen)days, block and slides for 5(five) years only from the time of receipt at the laboratory. No request ,for any of the above ,will be entertained after the due date.

### Reference

- i) Rosai and Ackerman's Surgical Pathology.
- ii) Modern Surgical Pathology.

**Gulshan Yadav, MD**  
Consultant Pathologist