

<b>Patient Name</b>	MISS. RUBIA	<b>Client Name</b>	City Lab, Bhiwadi	<b>Specimen Received</b>	02/07/17
<b>Age/Sex</b>	12/F	<b>Client Code</b>	MOLQ1021CM	<b>Specimen Type</b>	Tissue
<b>Patient ID</b>	011707020066	<b>Ref. Doctor</b>		<b>Collection Date</b>	02/07/17
<b>Specimen ID</b>	MOLQ/B-485/17			<b>Report Date</b>	05/07/17

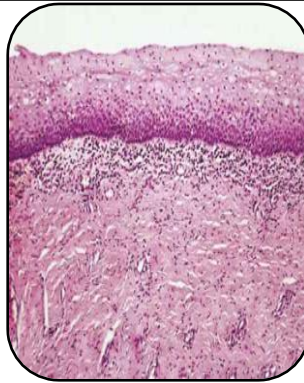
## SURGICAL PATHOLOGY REPORT

### Inflammatory lesion, Nasal Septum lesion

#### DIAGNOSIS

**INFLAMMATORY LESION.**

**ADVICE: KINDLY CORRELATE RADIOLOGICALLY AND CLINICALLY.**



#### SPECIMEN

Nasal Septum lesion

#### GROSS

- 1) Received multiple greyish white tissue piece.

#### Microscopy

- 1) Section examined shows fibrocollagenous tissue, small blood vessels and heavy inflammatory infiltrate (lymphocytes, polymorphs, plasma cells).
- 2) No granuloma seen.

**Note :** All biopsy specimen will be stored for 15 (fifteen)days, block and slides for 5(five) years only from the time of receipt at the laboratory. No request ,for any of the above ,will be entertained after the due date.

#### Reference

- i) Rosai and Ackerman's Surgical Pathology.
- ii) Modern Surgical Pathology.

A handwritten signature in black ink, appearing to read 'Gulshan', written over a light-colored rectangular background.

**Gulshan Yadav, MD**  
**Consultant Pathologist**