

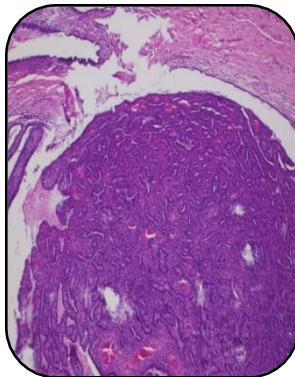
<b>Patient Name</b> MS. ASHMIN	<b>Client Name</b> Star Hospital	<b>Specimen Received</b> 25/06/2017
<b>Age/Sex</b> 26/F		<b>Specimen Type</b> Tissue
<b>Patient ID</b> 011706250064	<b>Client Code</b> MOLQ1255CM	<b>Collection Date</b> 25/06/2017
<b>Specimen ID</b> MOLQ/B-468/17	<b>Ref. Doctor</b> DR. DEEP SHIKHA	<b>Report Date</b> 01/07/2017

## SURGICAL PATHOLOGY REPORT

**Right Fallopian Tube confirmed and unremarkable, Right Fallopian Tube**

### DIAGNOSIS

**RIGHT FALLOPIAN TUBE CONFIRMED AND UNREMARKABLE.**



### SPECIMEN

Right Fallopian Tube

### GROSS

1) Received 1x1cm greyish white tissue piece.

### Microscopy

1) Section examined shows tubal lining epithelium with fibrocollagenous tissue.

**Note :** All biopsy specimen will be stored for 15 (fifteen)days, block and slides for 5(five) years only from the time of receipt at the laboratory. No request ,for any of the above ,will be entertained after the due date.

### Reference

- i) Rosai and Ackerman's Surgical Pathology.
- ii) Modern Surgical Pathology.

**Gulshan Yadav, MD**  
Consultant Pathologist

*Report generated at MolQ Laboratory, Gurgaon*