

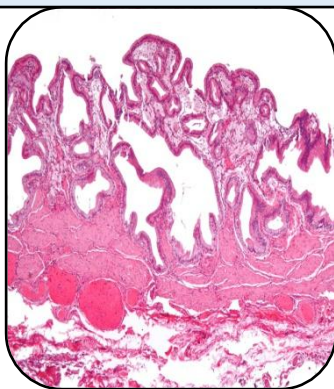
Patient Name	MR. SHADEV	Client Name	Vedic Hospital	Specimen Received	19/06/17
Age/Sex	50/M	Client Code	MOLQ1492CM	Specimen Type	Tissue
Patient ID	011706190225	Ref. Doctor		Collection Date	19/06/17
Specimen ID	MOLQ/B-448/17			Report Date	24/06/17

SURGICAL PATHOLOGY REPORT

Cholecystitis with Cholelithiasis, Gall Bladder

DIAGNOSIS

CHOLECYSTITIS WITH CHOLELITHIASIS.



SPECIMEN

Gall Bladder

GROSS

1) Received Autolyzed tissue 6x3cm long gall bladder with tiny stones.

Microscopy

1) Section examined shows ulcerative mucosa and Rokitansky-Aschoff sinuses with lymphocytes within fibrocollagenous tissue.

Note : All biopsy specimens will be stored for 15 (fifteen) days, block and slides for 5 (five) years only from the time of receipt at the laboratory. No request, for any of the above, will be entertained after the due date.

Reference

- i) Rosai and Ackerman's Surgical Pathology.
- ii) Modern Surgical Pathology.

Gulshan Yadav, MD
Consultant Pathologist