

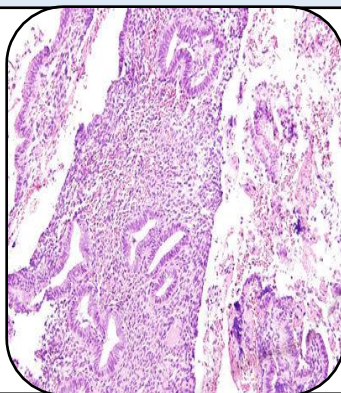
Patient Name	Mrs. KAVITA	Client Name	Shikha Health Care	Specimen Received	19/06/17
Age/Sex	45/F	Client Code	MolQ1519P	Specimen Type	Tissue
Patient ID	011706190120	Ref. Doctor		Collection Date	19/06/17
Specimen ID	MOLQ/B-445/17			Report Date	24/06/17

SURGICAL PATHOLOGY REPORT

Disordered Proliferative phase, Endometrium Biopsy

DIAGNOSIS

DISORDERED PROLIFERATIVE PHASE.



SPECIMEN

Endometrium Biopsy

GROSS

1) Received multiple greyish white tissue pieces.

Microscopy

- 1) Section examined shows small endometrial glands having round to oval nucleus and vacuoles.
- 2) Stroma shows mononuclear inflammatory cells.

Note : All biopsy specimen will be stored for 15 (fifteen) days, block and slides for 5 (five) years only from the time of receipt at the laboratory. No request, for any of the above, will be entertained after the due date.

Reference

- i) Rosai and Ackerman's Surgical Pathology.
- ii) Modern Surgical Pathology.

A handwritten signature in black ink, appearing to read 'Gulshan', written over a light blue rectangular background.

Gulshan Yadav, MD
Consultant Pathologist