

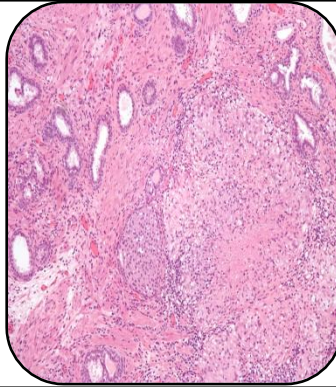
<b>Patient Name</b>	MRS. PUSHPA GARG	<b>Client Name</b>	Lifeaid Wellness Centre	<b>Specimen Received</b>	17/06/17
<b>Age/Sex</b>	64/F	<b>Client Code</b>	MOLQ1476CM	<b>Specimen Type</b>	Tissue
<b>Patient ID</b>	011706170128	<b>Ref. Doctor</b>		<b>Collection Date</b>	17/06/17
<b>Specimen ID</b>	MOLQ/B-435/17			<b>Report Date</b>	21/06/2017

## SURGICAL PATHOLOGY REPORT

**Non specific inflammation with Haemorrhoids, Haemorrhoids with fistula .**

### DIAGNOSIS

**NON SPECIFIC INFLAMMATION WITH HAEMORRHOIDS.**



### SPECIMEN

Haemorrhoids with fistula .

### GROSS

- 1) Received 4x2cm greyish white tissue piece with skin and opening on the skin.

### Microscopy

- 1) Section examined shows Squamous lining epithelium.
- 2) Deeper tissue shows fibrocollagenous tissue, mononuclear inflammatory cells and large number of blood vessels.

**Note :** All biopsy specimen will be stored for 15 (fifteen)days, block and slides for 5(five) years only from the time of receipt at the laboratory. No request ,for any of the above ,will be entertained after the due date.

### Reference

- i) Rosai and Ackerman's Surgical Pathology.
- ii) Modern Surgical Pathology.

A handwritten signature in black ink, appearing to read 'Gulshan', written over a white rectangular background.

**Gulshan Yadav, MD**  
**Consultant Pathologist**