

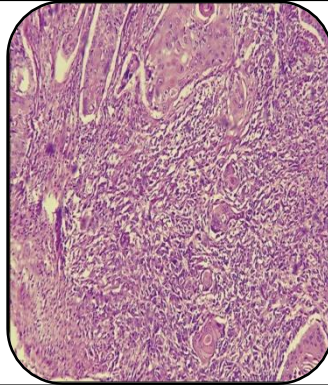
<b>Patient Name</b>	MRS. RAJKUMARI	<b>Client Name</b>	Ghosh Path Lab	<b>Specimen Received</b>	07/06/2017
<b>Age/Sex</b>	20/M	<b>Client Code</b>	MOLQ1123CM	<b>Specimen Type</b>	Tissue
<b>Patient ID</b>	011706070063	<b>Ref. Doctor</b>		<b>Collection Date</b>	07/06/2017
<b>Specimen ID</b>	MOLQ/B-405/17			<b>Report Date</b>	15/062017

## SURGICAL PATHOLOGY REPORT

**Dermoid Cyst both ovaries, 1) Left Ovarian cyst 2) Right Ovarian cyst**

### DIAGNOSIS

**DERMOID CYST BOTH OVARIES.**



### SPECIMEN

- 1) Left Ovarian cyst
- 2) Right Ovarian cyst

### GROSS

- 1) Received 9x10cm and 4x5cm greyish white tissue. Cut section shows cheesy material with hair.

### Microscopy

- 1) **Left ovarian:** Section examined shows lining epithelium having small round nucleus with fibrocollagenous tissue, keratin, small blood vessels.
- 2) **Right Ovarian:** Section examined squamous epithelium lining with fibrocollagenous tissue and keratin flakes and blood vessels.

**Note :** All biopsy specimen will be stored for 15 (fifteen)days, block and slides for 5(five) years only from the time of receipt at the laboratory. No request ,for any of the above ,will be entertained after the due date.

### Reference

- i) Rosai and Ackerman's Surgical Pathology.
- ii) Modern Surgical Pathology.

**Gulshan Yadav, MD**  
**Consultant Pathologist**