

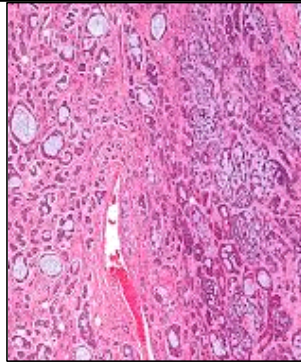
Patient Name	MRS. KRISHNA SHARMA	Client Name	Star Hospital	Specimen Received	04/06/2017
Age/Sex	40/F			Specimen Type	Tissue
Patient ID	011706040133	Client Code	MOLQ1255CM	Collection Date	04/06/2017
Specimen ID	MOLQ/B-398/17	Ref. Doctor		Report Date	09/06/2017

SURGICAL PATHOLOGY REPORT

Proliferative phase, Endometrium Biopsy

DIAGNOSIS

PROLIFERATIVE PHASE.



SPECIMEN

Endometrium Biopsy

GROSS

1) Received multiple greyish white tissue pieces.

Microscopy

- 1) Section examined shows small endometrial glands having small round nucleus.
- 2) Stroma shows mononuclear cells.
- 3) No granuloma and no malignant cells seen.

Note : All biopsy specimen will be stored for 15 (fifteen) days, block and slides for 5 (five) years only from the time of receipt at the laboratory. No request, for any of the above, will be entertained after the due date.

Reference

- i) Rosai and Ackerman's Surgical Pathology.
- ii) Modern Surgical Pathology.

Gulshan Yadav, MD
Consultant Pathologist

Report generated at MolQ Laboratory, Gurgaon