

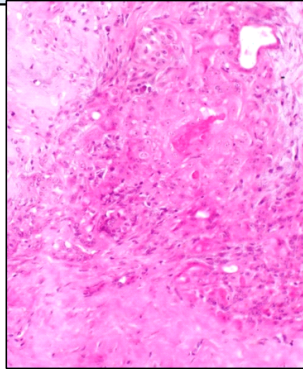
<b>Patient Name</b>	MR. NASEEM	<b>Client Name</b>	Ghosh Path Lab	<b>Specimen Received</b>	27/05/2017
<b>Age/Sex</b>	50/M			<b>Specimen Type</b>	Tissue
<b>Patient ID</b>	011705270065	<b>Client Code</b>	MOLQ.1123CM	<b>Collection Date</b>	27/05/2017
<b>Specimen ID</b>	MOLQ/B-380/17	<b>Ref. Doctor</b>		<b>Report Date</b>	03/06/2017

## SURGICAL PATHOLOGY REPORT

Neck Cyst.

### DIAGNOSIS

**BENIGN MESENCHYMAL LESION WITH INFLAMMATION .**



### SPECIMEN

Neck Cyst.

### GROSS

1) Received 1x1cm greyish white tissue pieces .

### Microscopy

1. Section examined shows fibrocollagenous tissue arrange in bundles and fascicles with nerve bundles with large number of inflammatory cells(lymphocytes, plasma cells, histiocytes, polymorphs).
2. No granuloma seen.

**Note :** All biopsy specimen will be stored for 15 (fifteen)days, block and slides for 5(five) years only from the time of receipt at the laboratory. No request ,for any of the above ,will be entertained after the due date.

### Reference

- i) Rosai and Ackerman's Surgical Pathology.
- ii) Modern Surgical Pathology.

A handwritten signature in black ink, appearing to read 'Gulshan', written over a light blue rectangular background.

**Gulshan Yadav, MD**  
**Consultant Pathologist**

*Report generated at MolQ Laboratory, Gurgaon*