

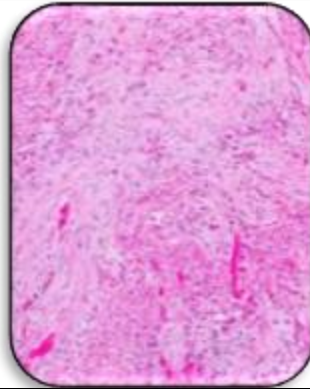
Patient Name	MR. SABHIR AHMAD	Client Name	S.R. Diagnostics	Specimen Received	22/05/2017
Age/Sex	46/M	Client Code	MolQ1528CM	Specimen Type	Tissue
Patient ID	011705220214	Ref. Doctor		Collection Date	22/05/2017
Specimen ID	MOLQ/B-362/17			Report Date	27/05/2017

SURGICAL PATHOLOGY REPORT

Left Epididymal cyst.

DIAGNOSIS

Left EPIDIDYMAL CYST.



SPECIMEN:

Left Epididymal cyst.

GROSS :

- 1) Received 4x2.5cm long greyish white tissue piece.
- 2) Cut section shows clear fluid .

Microscopy

- 1) Section examined shows dilated cysts lined by cuboidal lining epithelium with cilia.
- 2) No granuloma and no malignant cells seen.

Note : All biopsy specimen will be stored for 15 (fifteen) days, block and slides for 5 (five) years only from the time of receipt at the laboratory. No request, for any of the above, will be entertained after the due date.

Reference

- i) Rosai and Ackerman's Surgical Pathology.
- ii) Modern Surgical Pathology.

Gulshan Yadav, MD
Consultant Pathologist