

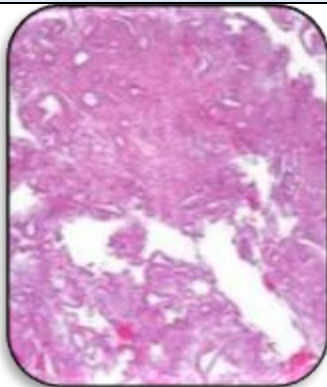
<b>Patient Name</b> MS. SHAGUPHATA KHARAM	<b>Client Name</b> Star Hospital	<b>Specimen Received</b> 16/05/2017
<b>Age/Sex</b> 22/F		<b>Specimen Type</b> Tissue
<b>Patient ID</b> 011705160201	<b>Client Code</b> MOLQ1255CM	<b>Collection Date</b> 16/05/2017
<b>Specimen ID</b> MOLQ/B-352/17	<b>Ref. Doctor</b> DR. DEEP SHIKHA	<b>Report Date</b> 24/05/2017

## SURGICAL PATHOLOGY REPORT

### Endometrial Polyp, Endometrium Biopsy.

#### DIAGNOSIS

**ENDOMETRIAL POLYP.**



#### SPECIMEN

Endometrium Biopsy.

#### GROSS

i) Received multiple greyish white tissue pieces.

#### Microscopy

- 1) Section examined shows small endometrial glands having cuboidal lining epithelium.
- 2) Few glands shows vacuoles.
- 3) Stroma shows mononuclear inflammatory cells.

**Note :** All biopsy specimen will be stored for 15 (fifteen) days, block and slides for 5 (five) years only from the time of receipt at the laboratory. No request, for any of the above, will be entertained after the due date.

#### Reference

- i) Rosai and Ackerman's Surgical Pathology.
- ii) Modern Surgical Pathology.

A handwritten signature in black ink, appearing to read 'Gulshan', written over a white rectangular background.

**Gulshan Yadav, MD**  
Consultant Pathologist