

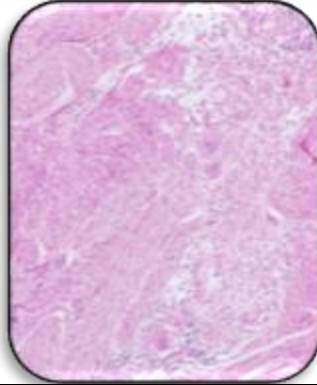
<b>Patient Name</b>	Mrs. RAJNI	<b>Client Name</b>	Kutumbh Diagnostic	<b>Specimen Received</b>	16/05/2017
<b>Age/Sex</b>	32/F		Center	<b>Specimen Type</b>	Tissue
<b>Patient ID</b>	011705160069	<b>Client Code</b>	MOLQ1379CM	<b>Collection Date</b>	16/05/2017
<b>Specimen ID</b>	MOLQ/B-348/17	<b>Ref. Doctor</b>		<b>Report Date</b>	23/05/2017

## SURGICAL PATHOLOGY REPORT

### Endometrial Biopsy.

#### DIAGNOSIS

**DISORDERED PROLIFERATIVE PHASE.**



#### SPECIMEN

Endometrial Biopsy.

#### GROSS

1) Received multiple greyish white tissue pieces.

#### Microscopy

- 1) Section examined shows small endometrial glands with columnar lining epithelium and oval nucleus.
- 2) Stroma shows mononuclear inflammatory cells.

**Note :** All biopsy specimen will be stored for 15 (fifteen) days, block and slides for 5 (five) years only from the time of receipt at the laboratory. No request, for any of the above, will be entertained after the due date.

#### Reference

- i) Rosai and Ackerman's Surgical Pathology.
- ii) Modern Surgical Pathology.

A handwritten signature in black ink, appearing to read 'Gulshan'.

**Gulshan Yadav, MD**  
**Consultant Pathologist**