

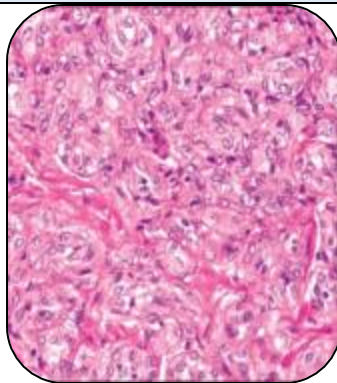
<b>Patient Name</b>	MR. PARVESH CHOUDHARY	<b>Client Name</b>	Pathdrug	<b>Specimen Received</b>	08/05/2017
<b>Age/Sex</b>	./M	<b>Client Code</b>	MOLQ1234A	<b>Specimen Type</b>	Tissue
<b>Patient ID</b>	011705090014	<b>Ref. Doctor</b>		<b>Collection Date</b>	08/05/2017
<b>Specimen ID</b>	MOLQ/B-331/17			<b>Report Date</b>	23/05/2017

## SURGICAL PATHOLOGY REPORT

### Granulation Tissue, Ulcer.

#### DIAGNOSIS

**GRANULATION TISSUE.**



#### SPECIMEN

Ulcer.

#### GROSS

Received 12x2cm greyish white tissue piece with skin.

#### Microscopy

- 1) Section examined shows fibrocollagenous tissue, blood vessels with mononuclear inflammatory cells and polymorphs.
- 2) No granuloma seen.

#### Reference

- i) Rosai and Ackerman's Surgical Pathology.
- ii) Modern Surgical Pathology.

**Gulshan Yadav, MD**  
**Consultant Pathologist**