

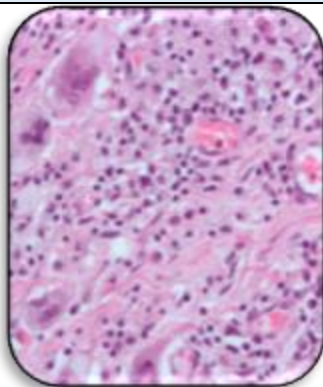
Patient Name MR. SANDEEP KUMAR	Client Name StarHospital	Specimen Received 10/05/2017
Age/Sex 28/M		Specimen Type Tissue
Patient ID 011705100270	Client Code MOLQ1255CM	Collection Date 10/05/2017
Specimen ID MOLQ/B-337/17	Ref. Doctor DR. AJAY KUMAR GUPTA	Report Date 19/05/2017

SURGICAL PATHOLOGY REPORT

Chronic infective lesion with granulation tissue, **Right Distal Tibia.**

DIAGNOSIS

CHRONIC INFECTIVE LESION WITH GRANULATION TISSUE.



SPECIMEN

Right Distal Tibia.

GROSS

i) Received multiple greyish white tissue pieces.

Microscopy

- 1) Section examined shows fibrocollagenous tissue, blood vessels, calcified tissue, mature adipose cells, bits of bony trabecular and mononuclear inflammatory cells (lymphocytes).
- 2) No well formed granuloma and no malignant cells seen.

Note : All biopsy specimen will be stored for 15 (fifteen) days, block and slides for 5 (five) years only from the time of receipt at the laboratory. No request, for any of the above, will be entertained after the due date.

Reference

- i) Rosai and Ackerman's Surgical Pathology.
- ii) Modern Surgical Pathology.

Gulshan Yadav, MD
Consultant Pathologist