

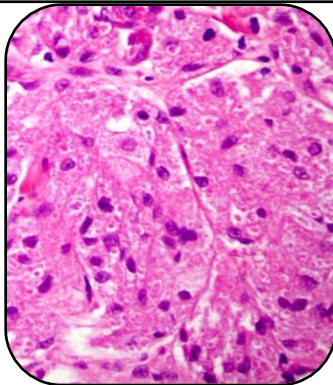
Patient Name	MRS. AMITA DAHYA	Client Name	Dhanwantri X-Ray Lab	Specimen Received	04/05/17
Age/Sex	26/F	Client Code	MOLQ1193CM	Specimen Type	Tissue
Patient ID	011705040158	Ref. Doctor	DR. N. KUMAR DAHIYA	Collection Date	04/05/17
Specimen ID	MOLQ/B-314/17			Report Date	10/05/17

SURGICAL PATHOLOGY REPORT

Benign Breast Lesion(Fibroadenoma), Right Breast.

DIAGNOSIS

BENIGN BREAST LESION(FIBROADENOMA).



SPECIMEN

Right Breast.

GROSS

i) Received three tissue pieces 1x3cm, 2x3cm and 3x2cm.

Microscopy

i) Section examined shows large number of ducts having cuboidal lining epithelium with small round nucleus with myoepithelial cell and large number of fibrocollagenous stroma.

Note : All biopsy specimen will be stored for 15 (fifteen)days, block and slides for 5(five) years only from the time of receipt at the laboratory. No request ,for any of the above ,will be entertained after the due date.

Reference

- i) Rosai and Ackerman's Surgical Pathology.
- ii) Modern Surgical Pathology.

Gulshan Yadav, MD
Consultant Pathologist