

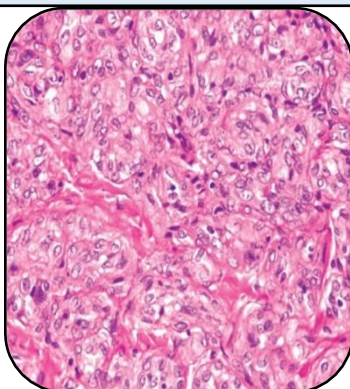
|                     |                      |                    |                        |                          |            |
|---------------------|----------------------|--------------------|------------------------|--------------------------|------------|
| <b>Patient Name</b> | MRS.PINKI W/O MAHESH | <b>Client Name</b> | Health Medicos, Rohtak | <b>Specimen Received</b> | 02/05/2017 |
| <b>Age/Sex</b>      | 23/F                 | <b>Client Code</b> | MOLQ1394CM             | <b>Specimen Type</b>     | Tissue     |
| <b>Patient ID</b>   | 011705020193         | <b>Ref. Doctor</b> |                        | <b>Collection Date</b>   | 02/05/2017 |
| <b>Specimen ID</b>  | MOLQ/B-311/17        |                    |                        | <b>Report Date</b>       | 06/05/2017 |

## SURGICAL PATHOLOGY REPORT

### Proliferative Phase, Endometrial.

#### DIAGNOSIS

**PROLIFERATIVE PHASE.**



#### SPECIMEN

Endometrial.

#### GROSS

- i) Received multiple greyish white tissue pieces.

#### Microscopy

- 1) Section examined shows endometrial glands having cuboidal lining epithelium with small round to oval nucleus.
- 2) Stroma shows mononuclear inflammatory cells.

**Note :** All biopsy specimen will be stored for 15 (fifteen)days, block and slides for 5(five) years only from the time of receipt at the laboratory. No request ,for any of the above ,will be entertained after the due date.

#### Reference

- i) Rosai and Ackerman's Surgical Pathology.
- ii) Modern Surgical Pathology.

**Gulshan Yadav, MD**  
Consultant Pathologist