

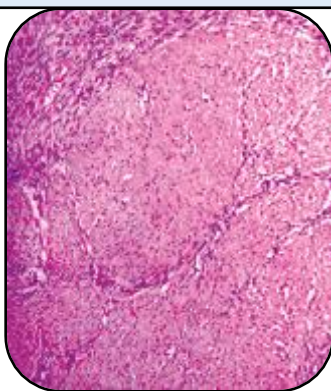
Patient Name MRS. MEENA SAINI	Client Name Star Hospital	Specimen Received 25/04/2017
Age/Sex 30/F		Specimen Type Tissue
Patient ID 011704250177	Client Code MOLQ1255CM	Collection Date 25/04/2017
Specimen ID MOLQ/B-297/17	Ref. Doctor	Report Date 06/05/2017

SURGICAL PATHOLOGY REPORT

LEFT FALLOPIAN TUBE.

DIAGNOSIS

LEFT FALLOPIAN TUBE CONFIRMED AND UNREMARKABLE.



SPECIMEN

Left fallopian tube

GROSS

1) Received 1x1cm greyish white tissue piece.

Microscopy

1) Section examined shows tubal lining epithelium having cuboidal cells with small round nucleus.

Note : All biopsy specimen will be stored for 15 (fifteen)days, block and slides for 5(five) years only from the time of receipt at the laboratory. No request ,for any of the above ,will be entertained after the due date.

Reference

- i) Rosai and Ackerman's Surgical Pathology.
- ii) Modern Surgical Pathology.

Gulshan Yadav, MD
Consultant Pathologist