

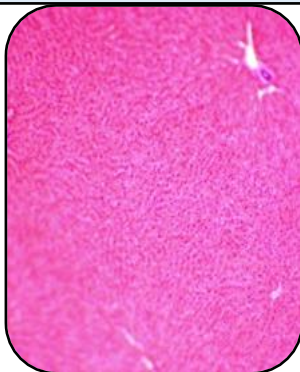
<b>Patient Name</b>	MS. SEEMA	<b>Client Name</b>	North Delhi Diagnostic	<b>Specimen Received</b>	26/04/17
<b>Age/Sex</b>	26/F	<b>Client Code</b>	MOLQ1219P	<b>Specimen Type</b>	Tissue
<b>Patient ID</b>	011704260137	<b>Ref. Doctor</b>	SKY LINE HOSPITAL	<b>Collection Date</b>	26/04/17
<b>Specimen ID</b>	MOLQ/B-302/17			<b>Report Date</b>	02/05/2017

## SURGICAL PATHOLOGY REPORT

### Acute Appendicitis, Appendix

#### DIAGNOSIS

**ACUTE APPENDICITIS**



#### **SPECIMEN:**

Appendix

#### **GROSS:**

- 1) Received 4x0.5cm greyish white tissue piece.
- 2) Cut section shows fecolith.

#### **Microscopy**

Section examined shows lymphoid follicles with ulcerative mucosa. Dermis tissue shows inflammatory infiltrate.

**Note :** All biopsy specimen will be stored for 15 (fifteen) days, block and slides for 5 (five) years only from the time of receipt at the laboratory. No request, for any of the above, will be entertained after the due date.

#### **Reference**

- i) Rosai and Ackerman's Surgical Pathology.
- ii) Modern Surgical Pathology.

**Gulshan Yadav, MD**  
Consultant Pathologist