

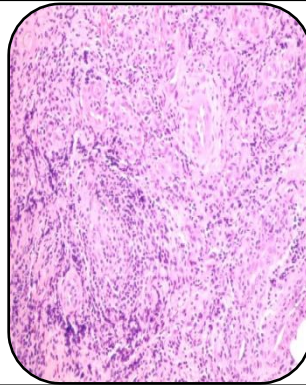
<b>Patient Name</b>	MR. GUDDU	<b>Client Name</b>	Ghosh Path Lab	<b>Specimen Received</b>	23/04/2017
<b>Age/Sex</b>	35/M	<b>Client Code</b>	MOLQ1123CM	<b>Specimen Type</b>	Tissue
<b>Patient ID</b>	011704240151	<b>Ref. Doctor</b>		<b>Collection Date</b>	23/04/2017
<b>Specimen ID</b>	MOLQ/B-286/17			<b>Report Date</b>	02/05/2017

## SURGICAL PATHOLOGY REPORT

### Hyperkeratotic Lesion, Sole swelling

#### DIAGNOSIS

**HYPERKERATOTIC LESION.**



#### SPECIMEN

Sole swelling .

#### GROSS

1) Received 3x2cm greyish white cystic tissue piece

#### Microscopy

- 1) Section examined shows Squamous epithelial lining epithelium with hyperkeratosis and parakeratosis.
- 2) Deeper tissue shows fibrocollagenous tissue blood vessels and inflammatory cells.

**Note :** All biopsy specimen will be stored for 15 (fifteen)days, block and slides for 5(five) years only from the time of receipt at the laboratory. No request ,for any of the above ,will be entertained after the due date.

#### Reference

- i) Rosai and Ackerman's Surgical Pathology.
- ii) Modern Surgical Pathology.

**Gulshan Yadav, MD**  
Consultant Pathologist