

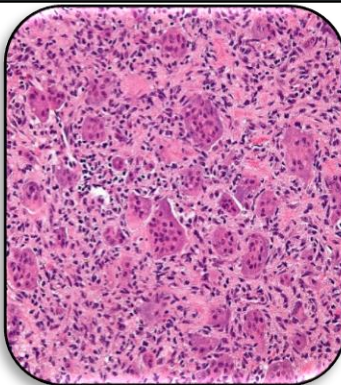
<b>Patient Name</b>	MR. DEEPAK DALAL	<b>Client Name</b>	MolQ Collection Centre	<b>Specimen Received</b>	20/04/2017
<b>Age/Sex</b>	42/M		NRR	<b>Specimen Type</b>	Tissue
<b>Patient ID</b>	021704200018	<b>Client Code</b>	MOLQ1251CC	<b>Collection Date</b>	20/04/2017
<b>Specimen ID</b>	MOLQ/B-283/17	<b>Ref. Doctor</b>	DR.NAVEEN FUTELA	<b>Report Date</b>	26/04/2017

## SURGICAL PATHOLOGY REPORT

### Benign mesenchymal lesion, Oral Cavity lesion

#### DIAGNOSIS

**BENIGN MESENCHYMAL LESION.**



#### SPECIMEN

Oral Cavity lesion

#### GROSS

i) Received 1x2cm greyish white tissue piece.

#### Microscopy

- 1) Section examined shows muscle bundles, fibrocollagenous tissue large number of blood vessels and inflammatory cells.
- 2) No granuloma and no malignant cells seen.

**Note :** All biopsy specimen will be stored for 15 (fifteen)days, block and slides for 5(five) years only from the time of receipt at the laboratory. No request ,for any of the above ,will be entertained after the due date.

#### Reference

- i) Rosai and Ackerman's Surgical Pathology.
- ii) Modern Surgical Pathology.

**Gulshan Yadav, MD**  
Consultant Pathologist

Report generated at MolQ Laboratory, Gurgaon