

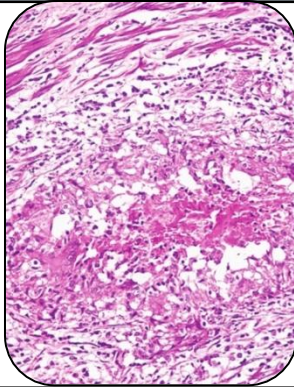
<b>Patient Name</b>	MRS. MOUTRISHA	<b>Client Name</b>	Health Medicos, Rohtak	<b>Specimen Received</b>	12/04/2017
<b>Age/Sex</b>	27/F	<b>Client Code</b>	MOLQ1394CM	<b>Specimen Type</b>	Tissue
<b>Patient ID</b>	011704120202	<b>Ref. Doctor</b>		<b>Collection Date</b>	12/04/2017
<b>Specimen ID</b>	MOLQ/B-268/17			<b>Report Date</b>	20/04/2017

## SURGICAL PATHOLOGY REPORT

### Disordered proliferative phase, Endometrium Biopsy

#### DIAGNOSIS

**DISORDERED PROLIFERATIVE PHASE.**



#### SPECIMEN

Endometrium Biopsy

#### GROSS

1) Received multiple greyish white tissue pieces.

#### Microscopy

- 1) Section examined shows small endometrial glands having cuboidal to columnar lining epithelium.
- 2) Stroma shows mononuclear inflammatory cells.
- 3) No granuloma and no malignant cells seen.

**Note :** All biopsy specimen will be stored for 15 (fifteen)days, block and slides for 5(five) years only from the time of receipt at the laboratory. No request ,for any of the above ,will be entertained after the due date.

#### Reference

- i) Rosai and Ackerman's Surgical Pathology.
- ii) Modern Surgical Pathology.

**Gulshan Yadav, MD**  
**Consultant Pathologist**