

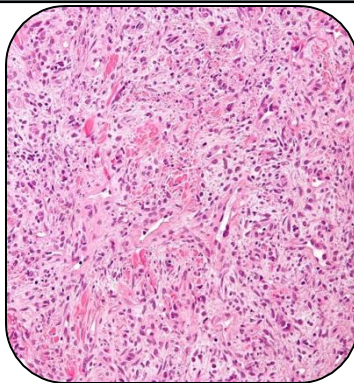
<b>Patient Name</b>	MRS. SONIA	<b>Client Name</b>	MolQ Collection Centre- V, Ambala	<b>Specimen Received</b>	12/04/17
<b>Age/Sex</b>	23/F	<b>Client Code</b>	MOLQ1207A	<b>Specimen Type</b>	Tissue
<b>Patient ID</b>	011704120082	<b>Ref. Doctor</b>	AMBALA CLINICAL LAB	<b>Collection Date</b>	12/04/17
<b>Specimen ID</b>	MOLQ/B-265/17			<b>Report Date</b>	19/04/17

## SURGICAL PATHOLOGY REPORT

### Benign mesenchymal lesion, Elbow tissue

#### DIAGNOSIS

**BENIGN MESENCHYMAL LESION.**



#### SPECIMEN

Elbow tissue

#### GROSS

1) Received 2x3cm and 1x1cm greyish white tissue piece.

#### Microscopy

- 1) Section examined shows Squamous lining epithelium having round to oval nucleus.
- 2) Dermis shows small blood vessels, fibrocollagenous tissue.
- 3) No granuloma and no malignant cells seen.

**Note :** All biopsy specimen will be stored for 15 (fifteen)days, block and slides for 5(five) years only from the time of receipt at the laboratory. No request ,for any of the above ,will be entertained after the due date.

#### Reference

- i) Rosai and Ackerman's Surgical Pathology.
- ii) Modern Surgical Pathology.

**Gulshan Yadav, MD**  
Consultant Pathologist