

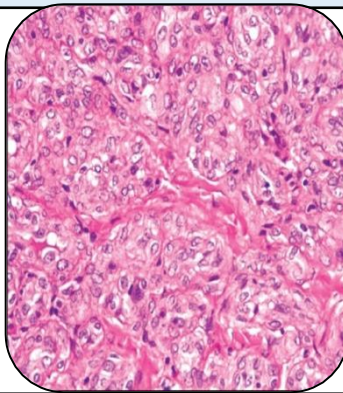
<b>Patient Name</b>	MR. RAJESH RAWAT	<b>Client Name</b>	Dhanwantri X-Ray Lab	<b>Specimen Received</b>	07/04/2017
<b>Age/Sex</b>	42/M	<b>Client Code</b>	MOLQ1193CW	<b>Specimen Type</b>	Tissue
<b>Patient ID</b>	011704070092	<b>Ref. Doctor</b>	BHAWNA PANDEY	<b>Collection Date</b>	07/04/2017
<b>Specimen ID</b>	MOLQ/B-252/17			<b>Report Date</b>	14/04/2017

## SURGICAL PATHOLOGY REPORT

### Capillary haemangioma, Oral cavity

#### DIAGNOSIS

**CAPILLARY HAEMANGIOMA.**



#### SPECIMEN

Oral cavity

#### GROSS

1) Received 1x0.5cm single tissue piece greyish white tissue piece.

#### Microscopy

- 1) Section examined shows Squamous lining epithelium with round to oval nucleus.
- 2) Deeper tissue shows fibrocollagenous tissue, mononuclear inflammatory cells and blood vessels.

**Note :** All biopsy specimen will be stored for 15 (fifteen)days, block and slides for 5(five) years only from the time of receipt at the laboratory. No request ,for any of the above ,will be entertained after the due date.

#### Reference

- i) Rosai and Ackerman's Surgical Pathology.
- ii) Modern Surgical Pathology.

**Gulshan Yadav, MD**  
**Consultant Pathologist**