

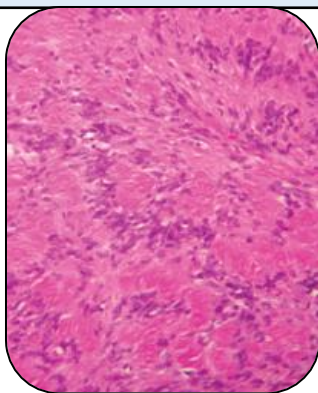
Patient Name	MR. MUNNA	Client Name	Ghosh Path Lab	Specimen Received	06/04/2017
Age/Sex	35/M	Client Code	MOLQ1123CM	Specimen Type	Tissue
Patient ID	011704060067	Ref. Doctor		Collection Date	06/04/2017
Specimen ID	MOLQ/B-243/17			Report Date	14/04/2017

SURGICAL PATHOLOGY REPORT

Benign salivary gland lesion with Fibrolipoma, Parotid

DIAGNOSIS

BENIGN SALIVARY GLAND LESION WITH FIBROLIPOMA.



SPECIMEN

Parotid

GROSS

- 1) Received 5x4cm and 4x3cm capsulated two tissue pieces greyish white.

Microscopy

- 1) Section examined shows large number of glands having cuboidal lining epithelium with small round nucleus surrounded by fibrocollagenous tissue, mature adipose cells, blood vessels and ducts with mononuclear inflammatory cells.
- 2) No granuloma and no malignant cells seen.

Note : All biopsy specimen will be stored for 15 (fifteen)days, block and slides for 5(five) years only from the time of receipt at the laboratory. No request ,for any of the above ,will be entertained after the due date.

Reference

- i) Rosai and Ackerman's Surgical Pathology.
- ii) Modern Surgical Pathology.

Gulshan Yadav, MD
Consultant Pathologist