

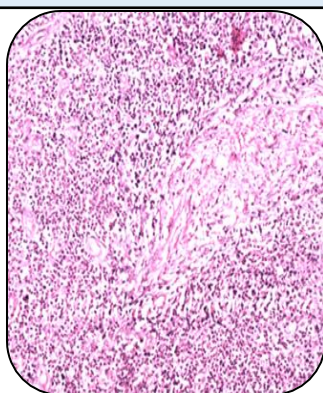
| | | | | | |
|---------------------|---------------|--------------------|----------------|--------------------------|------------|
| Patient Name | MRS. KAMLESH | Client Name | Vedic Hospital | Specimen Received | 04/04/2017 |
| Age/Sex | 35/F | Client Code | MOLQ1492CM | Specimen Type | Tissue |
| Patient ID | 011704040153 | Ref. Doctor | | Collection Date | 04/04/2017 |
| Specimen ID | MOLQ/B-237/17 | | | Report Date | 13/04/2017 |

SURGICAL PATHOLOGY REPORT

Cholecystitis with Cholelithiasis, Gall Bladder

DIAGNOSIS

CHOLECYSTITIS WITH CHOLELITHIASIS



SPECIMEN

Gall Bladder

GROSS

- Received 7x2.3cm long gall bladder with stone.

Microscopy

- Section examined shows ulcerative mucosa and Rokitansky-Aschoff sinuses with lymphocytes within fibrocollagenous tissue.

Note : All biopsy specimens will be stored for 15 (fifteen) days, block and slides for 5 (five) years only from the time of receipt at the laboratory. No request, for any of the above, will be entertained after the due date.

Reference

- Rosai and Ackerman's Surgical Pathology.
- Modern Surgical Pathology.

Gulshan Yadav, MD
Consultant Pathologist