

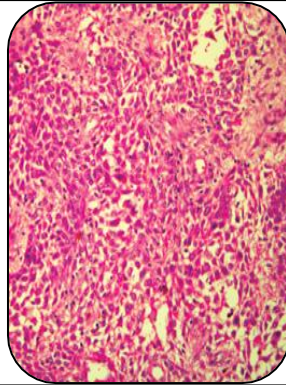
<b>Patient Name</b>	Miss. DIVYANSHI	<b>Client Name</b>	Agarwal Pathology, Agra	<b>Specimen Received</b>	03/04/2017
<b>Age/Sex</b>	05/f	<b>Client Code</b>	MOLQ1420CM	<b>Specimen Type</b>	Tissue
<b>Patient ID</b>	011704030246	<b>Ref. Doctor</b>		<b>Collection Date</b>	03/04/2017
<b>Specimen ID</b>	MOLQ/B-234/17			<b>Report Date</b>	13/04/2017

## SURGICAL PATHOLOGY REPORT

### Benign mesenchymal lesion, Conjunctival cyst.

#### DIAGNOSIS

**BENIGN MESENCHYMAL LESION.**



#### SPECIMEN

Conjunctival cyst

#### GROSS

1) Received 1x1cm greyish white tissue piece.

#### Microscopy

- 1) Section examined shows squamous lining epithelium with round to oval nucleus.
- 2) Dermis shows fibrocollagenous tissue, mature adipose cells and large number of small blood vessels.

**Note :** All biopsy specimen will be stored for 15 (fifteen)days, block and slides for 5(five) years only from the time of receipt at the laboratory. No request ,for any of the above ,will be entertained after the due date.

#### Reference

- i) Rosai and Ackerman's Surgical Pathology.
- ii) Modern Surgical Pathology.

**Gulshan Yadav, MD**  
Consultant Pathologist