

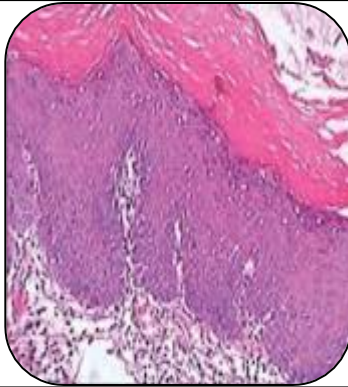
Patient Name	MR. SUNIL YADAV	Client Name	Shree Bala Ji Path Lab	Specimen Received	03/04/2017
Age/Sex	40/M	Client Code	MOLQ1079P	Specimen Type	Tissue
Patient ID	011704030201			Collection Date	03/04/2017
Specimen ID	MOLQ/B-233/17	Ref. Doctor		Report Date	13/04/2017

SURGICAL PATHOLOGY REPORT

Hyperkerrototic lesion, Scalp swelling

DIAGNOSIS

HYPERKEROTOTIC LESION.



SPECIMEN

Scalp swelling

GROSS

1) Received 1x1cm and 1x2cm greyish white tissue piece.

Microscopy

- Section examined shows Squamous lining epithelium with small round to oval nucleus with marked Hyperkeratosis and Parakeratosis.
- Dermis shows fibrocollagenous tissue, blood vessels and mononuclear inflammatory cells.

Note : All biopsy specimen will be stored for 15 (fifteen)days, block and slides for 5(five) years only from the time of receipt at the laboratory. No request ,for any of the above ,will be entertained after the due date.

Reference

- Rosai and Ackerman's Surgical Pathology.
- Modern Surgical Pathology.

Gulshan Yadav, MD
Consultant Pathologist