

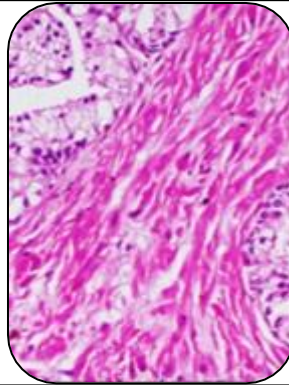
<b>Patient Name</b>	MR. MAHAVEER SINGH	<b>Client Name</b>	North Delhi Diagnostic	<b>Specimen Received</b>	01/04/2017
<b>Age/Sex</b>	65/M	<b>Client Code</b>	MOLQ1219P	<b>Specimen Type</b>	Tissue
<b>Patient ID</b>	011704010015	<b>Ref. Doctor</b>	SKY LINE HOSPITAL	<b>Collection Date</b>	01/04/2017
<b>Specimen ID</b>	MOLQ/B-229/17			<b>Report Date</b>	10/04/2017

## SURGICAL PATHOLOGY REPORT

### Benign prostatic Hyperplasia, T.U.R.P

#### DIAGNOSIS

**Benign prostatic Hyperplasia**



#### SPECIMEN:

T.U.R.P

#### GROSS:

1. Received multiple 4X2.5CM greyish white tissue piece.

#### Microscopy

- 1) Section examined shows bilayered prostatic glands with columnar lining epithelium and projection in the lumen with small round to oval nucleus surrounded by large number of fibrocollagenous tissue and mononuclear inflammatory cells.

**Note :** All biopsy specimen will be stored for 15 (fifteen)days, block and slides for 5(five) years only from the time of receipt at the laboratory. No request ,for any of the above ,will be entertained after the due date.

#### Reference

- i) Rosai and Ackerman's Surgical Pathology.
- ii) Modern Surgical Pathology.

**Gulshan Yadav, MD**  
Consultant Pathologist