

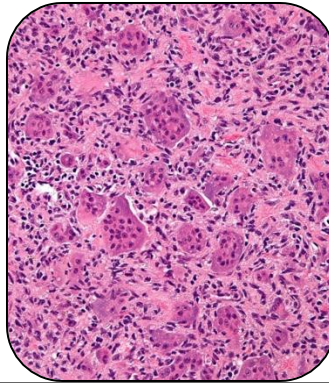
<b>Patient Name</b>	MRS. ANITA GUPTA	<b>Client Name</b>	Agarwal Pathology, Agra	<b>Specimen Received</b>	31/03/2017
<b>Age/Sex</b>	47/F	<b>Client Code</b>	MOLQ1420CM	<b>Specimen Type</b>	Tissue
<b>Patient ID</b>	011703310238	<b>Ref. Doctor</b>		<b>Collection Date</b>	31/03/2017
<b>Specimen ID</b>	MOLQ/B-224/17			<b>Report Date</b>	06/04/2017

## SURGICAL PATHOLOGY REPORT

### Benign mesenchymal Lesion, Lipoma.

#### DIAGNOSIS

**BENIGN MESENCHYMAL LESION.**



#### SPECIMEN

Lipoma.

#### GROSS

1) Received 4x5cm greyish white tissue piece with skin.

#### Microscopy

- 1) Section examined shows Squamous lining epithelium fibrocollagenous tissue, blood vessels.
- 2) No granuloma and no malignant cells seen.

**Note :** All biopsy specimen will be stored for 15 (fifteen)days, block and slides for 5(five) years only from the time of receipt at the laboratory. No request ,for any of the above ,will be entertained after the due date.

#### Reference

- i) Rosai and Ackerman's Surgical Pathology.
- ii) Modern Surgical Pathology.

**Gulshan Yadav, MD**  
Consultant Pathologist