

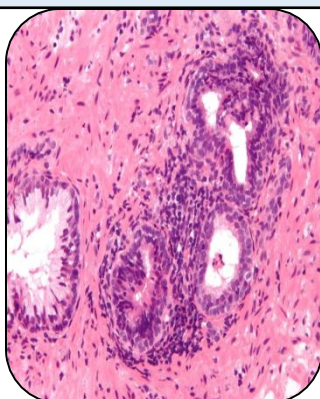
Patient Name	MR. BRIJ MOHAN	Client Name	RG Stone Urology & Laparoscopy Hospital	Specimen Received	31/03/2017
Age/Sex	74/M	Client Code	MOLQ1550CM	Specimen Type	Tissue
Patient ID	011703310168	Ref. Doctor		Collection Date	31/03/2017
Specimen ID	MOLQ/B-222/17			Report Date	06/04/2017

SURGICAL PATHOLOGY REPORT

Benign prostatic Hyperplasia with prostatitis, Prostate

DIAGNOSIS

BENIGN PROSTATIC HYPERPLASIA WITH PROSTATITIS.



SPECIMEN:

Prostate

GROSS :

1) Received 4.5x3cm multiple greyish white tissue piece.

Microscopy

1) Section examined shows bilayered prostatic glands with columnar lining epithelium and projection in the lumen with small round to oval nucleus surrounded by large number of fibrocollagenous tissue and mononuclear inflammatory cells.

Note : All biopsy specimen will be stored for 15 (fifteen) days, block and slides for 5 (five) years only from the time of receipt at the laboratory. No request, for any of the above, will be entertained after the due date.

Reference

- i) Rosai and Ackerman's Surgical Pathology.
- ii) Modern Surgical Pathology.

Gulshan Yadav, MD
Consultant Pathologist