

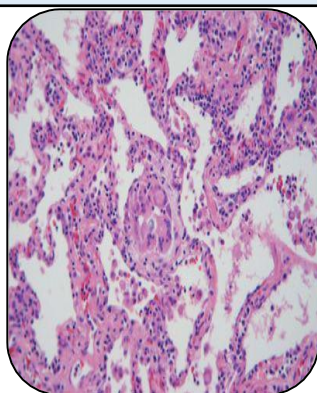
<b>Patient Name</b>	MR. ABDUL SATTAR	<b>Client Name</b>	Ghosh Path Lab	<b>Specimen Received</b>	29/03/2017
<b>Age/Sex</b>	50/M	<b>Client Code</b>	MOLQ1123CM	<b>Specimen Type</b>	Tissue
<b>Patient ID</b>	011703290069	<b>Ref. Doctor</b>		<b>Collection Date</b>	29/03/2017
<b>Specimen ID</b>	MOLQ/B-215/17			<b>Report Date</b>	04/04/2017

## SURGICAL PATHOLOGY REPORT

### Non specific inflammation, Hernia

#### DIAGNOSIS

**NON SPECIFIC INFLAMMATION**



#### SPECIMEN

Hernia

#### GROSS

- 1) Received 1x2cm greyish white tissue piece.

#### Microscopy

- 1) Section examined shows mature adipose cells, fibrocollagenous tissue with large number of inflammatory cells (lymphocytes, plasma cells, polymorphs and blood vessels).
- 2) No granuloma and no malignant cells seen.

**Note :** All biopsy specimen will be stored for 15 (fifteen)days, block and slides for 5(five) years only from the time of receipt at the laboratory. No request ,for any of the above ,will be entertained after the due date.

#### Reference

- i) Rosai and Ackerman's Surgical Pathology.
- ii) Modern Surgical Pathology.

**Gulshan Yadav, MD**  
Consultant Pathologist