

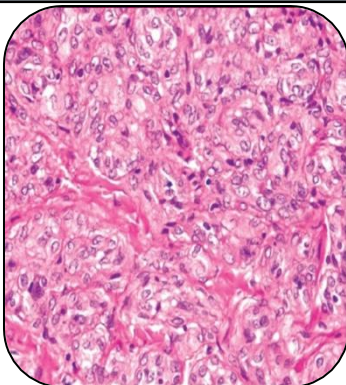
<b>Patient Name</b>	MS. REKHA	<b>Client Name</b>	Kailash Nursing Home	<b>Specimen Received</b>	28/03/2017
<b>Age/Sex</b>	21/F	<b>Client Code</b>	MOLQ1171P	<b>Specimen Type</b>	Tissue
<b>Patient ID</b>	011703280022	<b>Ref. Doctor</b>	DR.A.KOCHHAR	<b>Collection Date</b>	28/03/2017
<b>Specimen ID</b>	MOLQ/B-206/17			<b>Report Date</b>	31/03/2017

## SURGICAL PATHOLOGY REPORT

### proliferative phase , Endometrial Biopsy

#### DIAGNOSIS

**PROLIFERATIVE PHASE.**



#### SPECIMEN

Endometrial Biopsy

#### GROSS

i) Received multiple greyish white tissue pieces.

#### Microscopy

- 1) Section examined shows few small endometrial glands having cuboidal lining epithelium with small round nucleus.
- 2) Stroma shows RBC and mononuclear inflammatory cells.

**Note :** All biopsy specimen will be stored for 15 (fifteen)days, block and slides for 5(five) years only from the time of receipt at the laboratory. No request ,for any of the above ,will be entertained after the due date.

#### Reference

- i) Rosai and Ackerman's Surgical Pathology.
- ii) Modern Surgical Pathology.

A handwritten signature in black ink, appearing to read 'Gulshan', written over a light-colored rectangular background.

**Gulshan Yadav, MD**  
**Consultant Pathologist**

*Report generated at MolQ Laboratory, Gurgaon*