

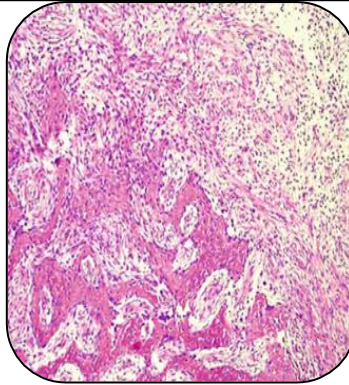
<b>Patient Name</b>	MR. ARPAN	<b>Client Name</b>	Dhanwantri X-Ray Lab	<b>Specimen Received</b>	26/03/2017
<b>Age/Sex</b>	41/M	<b>Client Code</b>	MOLQ1193CW	<b>Specimen Type</b>	Tissue
<b>Patient ID</b>	011703260100	<b>Ref. Doctor</b>	DR. MANOJ KUMAR	<b>Collection Date</b>	26/03/2017
<b>Specimen ID</b>	MOLQ/B-202/17			<b>Report Date</b>	31/03/2017

## SURGICAL PATHOLOGY REPORT

### Benign fibro-osseous Lesion , Periapical

#### DIAGNOSIS

**BENIGN FIBRO-OSSEOUS LESION.**



#### SPECIMEN

Periapical.

#### GROSS

1) Received multiple greyish white tissue pieces.

#### Microscopy

- 1) Section examined shows fibrocollagenous tissue , small blood vessels and calcified tissue.
- 2) No granuloma and no malignant cells seen.

**Note :** All biopsy specimen will be stored for 15 (fifteen)days, block and slides for 5(five) years only from the time of receipt at the laboratory. No request ,for any of the above ,will be entertained after the due date

#### Reference

- i) Rosai and Ackerman's Surgical Pathology.
- ii) Modern Surgical Pathology.

**Gulshan Yadav, MD**  
Consultant Pathologist