

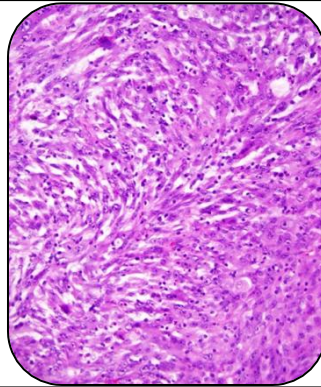
Patient Name	MR. VINOD	Client Name	City Lab, Bhiwadi	Specimen Received	20/03/2017
Age/Sex	25/M	Client Code	MOLQ1021CM	Specimen Type	Tissue
Patient ID	011703200225	Ref. Doctor		Collection Date	20/03/2017
Specimen ID	MOLQ/B-187/17			Report Date	25/03/2017

SURGICAL PATHOLOGY REPORT

Partial atrophy with maturation arrest, Right Testis

DIAGNOSIS

PARTIAL ATROPHY WITH MATURATION ARREST.



SPECIMEN

Right Testis.

GROSS

- Received small 0.1x0.2cm greyish white tissue piece in normal saline[Autolyzed tissue].

Microscopy

- Section examined shows large number of seminiferous tubules with immature spermatogenic cells and sertoli cells with spermatids.
- Few tubules shows thick basement membrane.

Note : All biopsy specimen will be stored for 15 (fifteen)days, block and slides for 5(five) years only from the time of receipt at the laboratory. No request ,for any of the above ,will be entertained after the due date.

Reference

- Rosai and Ackerman's Surgical Pathology.
- Modern Surgical Pathology.

Gulshan Yadav, MD
Consultant Pathologist