

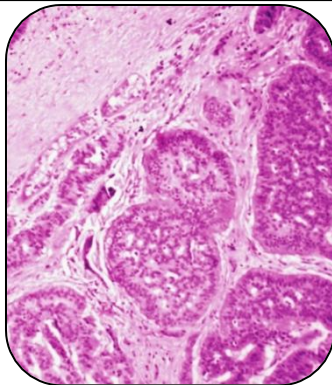
| | | | | | |
|---------------------|---------------|--------------------|----------------|--------------------------|------------|
| Patient Name | MR. HARIOM | Client Name | Vedic Hospital | Specimen Received | 17/03/2017 |
| Age/Sex | 42/M | Client Code | MOLQ1492CM | Specimen Type | Tissue |
| Patient ID | 011703170132 | Ref. Doctor | | Collection Date | 17/03/2017 |
| Specimen ID | MOLQ/B-180/17 | | | Report Date | 23/03/2017 |

SURGICAL PATHOLOGY REPORT

Dermoid Cyst , Cyst Scalp

DIAGNOSIS

DERMOID CYST.



SPECIMEN

Cyst Scalp

GROSS

1) Received 1x1cm greyish white tissue piece.

Microscopy

- 1) Section examined shows fibrocollagenous tissue, glands, blood vessels.
- 2) No granuloma and no malignant cells seen.

Note : All biopsy specimen will be stored for 15 (fifteen)days, block and slides for 5(five) years only from the time of receipt at the laboratory. No request ,for any of the above ,will be entertained after the due date.

Reference

- i) Rosai and Ackerman's Surgical Pathology.
- ii) Modern Surgical Pathology.

Gulshan Yadav, MD
Consultant Pathologist