

Patient Name	MR. DANIEL CYALL	Client Name	Chauhan Hospital	Specimen Received	16/03/2017
Age/Sex	64/M	Client Code	MOLQ1020P	Specimen Type	Tissue
Patient ID	011703160200	Ref. Doctor		Collection Date	16/03/2017
Specimen ID	MOLQ/B-178/17			Report Date	23/03/2017

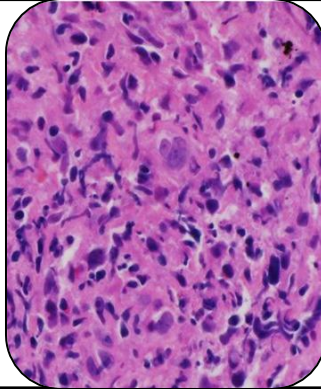
SURGICAL PATHOLOGY REPORT

Inflammatory lesion, Tissue sub diaphragmatic

DIAGNOSIS

INFLAMMATORY LESION.

ADVICE: Kindly correlate clinically and radiologically.



SPECIMEN

Tissue sub diaphragmatic

GROSS

1) Received multiple greyish white tissue piece.

Microscopy

- 1) Section examined shows fibrocollagenous tissue with scattered lymphocytes, plasma cells polymorphs with RBC and degenerated cells.
- 2) No malignant and no granuloma seen in sample received .

Note : All biopsy specimen will be stored for 15 (fifteen)days, block and slides for 5(five) years only from the time of receipt at the laboratory. No request ,for any of the above ,will be entertained after the due date.

Reference

- i) Rosai and Ackerman's Surgical Pathology.
- ii) Modern Surgical Pathology.

Gulshan Yadav, MD
Consultant Pathologist