

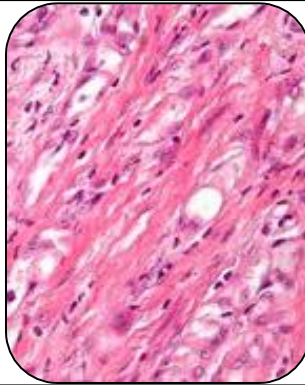
Patient Name	MRS. LATIFAN	Client Name	Ghosh Path Lab	Specimen Received	11/03/2017
Age/Sex	36/F	Client Code	MOLQ1123CM	Specimen Type	Tissue
Patient ID	011703110179	Ref. Doctor		Collection Date	11/03/2017
Specimen ID	MOLQ/B-171/17			Report Date	18/03/2017

SURGICAL PATHOLOGY REPORT

Chronic cervicitis with hemorrhagic cyst, Uterus with Cervix

DIAGNOSIS

CHRONIC CERVICITIS WITH HEMORRHAGIC CYST.



SPECIMEN

Uterus with Cervix

GROSS

- 1) Received 8x5cm long uterus with cervix with bilateral adenaxa.
- 2) Ovary size 4x2.5cm and 3x2.6cm with cyst.
- 3) Cyst[1x1cm uniloculated].
- 4) Cut section from the cyst shows serous fluid.

Microscopy

- 1) Section examined shows Small endometrial glands in proliferative phase.
- 2) Myometrium in unremarkable.
- 3) Cervix shows squamous lining epithelium with mononuclear inflammatory cells.
- 4) Ovary shows leuteal and hemorrhagic cyst and tube unremarkable.
- 5) Other ovary shows leuteal cyst and tube unremarkable.

Note : All biopsy specimen will be stored for 15 (fifteen)days, block and slides for 5(five) years only from the time of receipt at the laboratory. No request ,for any of the above ,will be entertained after the due date.

Reference

- i) Rosai and Ackerman's Surgical Pathology.
- ii) Modern Surgical Pathology.

Gulshan Yadav, MD
Consultant Pathologist

Report generated at MolQ Laboratory, Gurgaon