

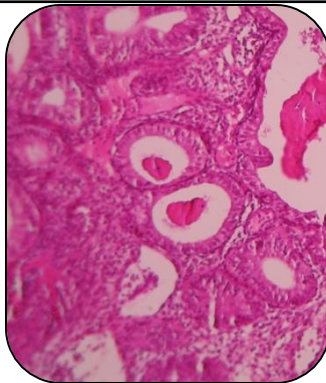
<b>Patient Name</b>	MRS. KRANTI	<b>Client Name</b>	Gumti Diagnostics	<b>Specimen Received</b>	04/03/2017
<b>Age/Sex</b>	50/F	<b>Client Code</b>	MOLQ1208A	<b>Specimen Type</b>	Tissue
<b>Patient ID</b>	011703040066	<b>Ref. Doctor</b>	JAIN NURSING HOME	<b>Collection Date</b>	04/03/2017
<b>Specimen ID</b>	MOLQ/B-156/17			<b>Report Date</b>	08/03/2017

## SURGICAL PATHOLOGY REPORT

### Simple hyperplasia without Atypia , Endometrial Biopsy.

#### DIAGNOSIS

**SIMPLE HYPERPLASIA WITHOUT ATYPIA.**



#### SPECIMEN

Endometrial Biopsy.

#### GROSS

i) Received multiple greyish white tissue pieces.

#### Microscopy

- 1) Section examined shows small endometrial glands having cuboidal lining epithelium with round to oval nucleus.
- 2) Stroma shows mononuclear inflammatory cells.

**Note :** All biopsy specimen will be stored for 15 (fifteen)days, block and slides for 5(five) years only from the time of receipt at the laboratory. No request ,for any of the above ,will be entertained after the due date.

#### Reference

- i) Rosai and Ackerman's Surgical Pathology.
- ii) Modern Surgical Pathology.

**Gulshan Yadav, MD**  
Consultant Pathologist

Report generated at MolQ Laboratory, Gurgaon