

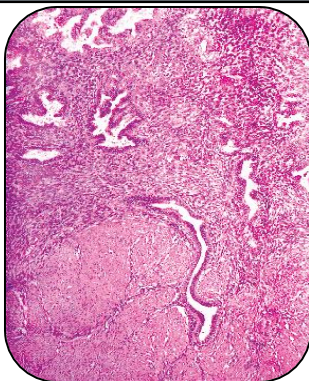
Patient Name	Ms. JYOTI	Client Name	Satyam Hospital, MadanPuri	Specimen Received	26/02/2017
Age/Sex	24/F	Client Code	MOLQ1413CM	Specimen Type	Tissue
Patient ID	011702260048	Ref. Doctor		Collection Date	26/02/2017
Specimen ID	MOLQ/B-138/17			Report Date	04/03/2017

SURGICAL PATHOLOGY REPORT

Fallopian tube confirmed and unremarkable, Left Fallopian Tube

DIAGNOSIS

FALLOPIAN TUBE CONFIRMED AND UNREMARKABLE.



SPECIMEN

Left Fallopian Tube

GROSS

1) Received Autolyzed tissue 1x1cm left fallopian tube.

Microscopy

1) Section examined shows lining epithelium having cuboidal cells with oval nucleus.

Note : All biopsy specimen will be stored for 15 (fifteen)days, block and slides for 5(five) years only from the time of receipt at the laboratory. No request ,for any of the above ,will be entertained after the due date.

Reference

- i) Rosai and Ackerman's Surgical Pathology.
- ii) Modern Surgical Pathology.

A handwritten signature in black ink, appearing to read 'Gulshan', written over a white rectangular background.

Gulshan Yadav, MD
Consultant Pathologist