

Patient Name	MR. JAY KRISHAN	Client Name	Vedic Hospital	Specimen Received	23/02/2017
Age/Sex	70/M	Client Code	MOLQ1492CM	Specimen Type	Tissue
Patient ID	011702230180	Ref. Doctor		Collection Date	23/02/2017
Specimen ID	MOLQ/B-92/17			Report Date	03/03/2017

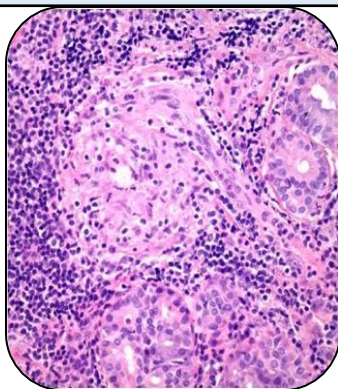
SURGICAL PATHOLOGY REPORT

Atypical epithelial cell Lesion[? Inflammatory? SCC], Tongue Growth

DIAGNOSIS

ATYPICAL EPITHELIAL CELL LESION[? INFLAMMATORY? SCC].

CYTOKERATIN[IHC].



SPECIMEN

Tongue Growth

GROSS

1) Received 1x1cm greyish white tissue piece.

Microscopy

- 1) Section examined shows Squamous epithelial cells in sheets having round to oval vesicular nucleus with large number of inflammatory mild atypia of cells.
- 2) Section also shows large number of small blood vessels and fibrocollagenous tissue.

Note : All biopsy specimen will be stored for 15 (fifteen)days, block and slides for 5(five) years only from the time of receipt at the laboratory. No request ,for any of the above ,will be entertained after the due date.

Reference

- i) Rosai and Ackerman's Surgical Pathology.
- ii) Modern Surgical Pathology.

Gulshan Yadav, MD
Consultant Pathologist