

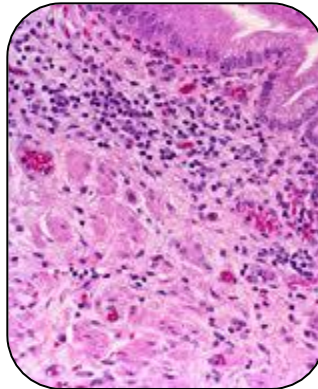
<b>Patient Name</b>	MR. PARMOD	<b>Client Name</b>	Kriti Hospital	<b>Specimen Received</b>	19/02/2017
<b>Age/Sex</b>	33/M	<b>Client Code</b>	MOLQ1112CM	<b>Specimen Type</b>	Tissue
<b>Patient ID</b>	011702190124	<b>Ref. Doctor</b>		<b>Collection Date</b>	19/02/2017
<b>Specimen ID</b>	MOLQ/B-116/17			<b>Report Date</b>	23/01/2017

## SURGICAL PATHOLOGY REPORT

### Cholecystitis with Cholelithiasis, Gall Bladder.

#### DIAGNOSIS

**CHOLECYSTITIS WITH CHOLELITHIASIS.**



#### SPECIMEN:

Gall Bladder.

#### GROSS :

- 1) Received 7.8x2.9cm long gall bladder.
- 2) Cut section shows multiple stones.

#### Microscopy

- i) Section examined shows ulcerative mucosa and rokitansky aschoff sinus with lymphocyte within fibrocollagenous tissue.

**Note :** All biopsy specimen will be stored for 15 (fifteen)days, block and slides for 5(five) years only from the time of receipt at the laboratory. No request ,for any of the above ,will be entertained after the due date.

#### Reference

- i) Rosai and Ackerman's Surgical Pathology.
- ii) Modern Surgical Pathology.

**Gulshan Yadav, MD**  
Consultant Pathologist