

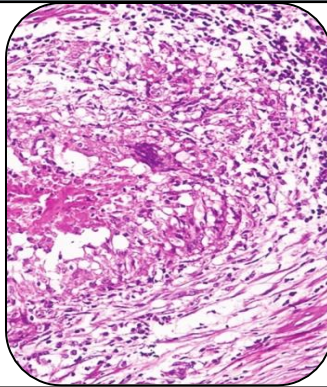
Patient Name	MRS. PREETI SHARMA	Client Name	Agarwal Pathology, Agra	Specimen Received	13/02/2017
Age/Sex	30/F	Client Code	MOLQ1420CM	Specimen Type	Tissue
Patient ID	011702130228	Ref. Doctor		Collection Date	13/02/2017
Specimen ID	MOLQ/B-102/17			Report Date	19/02/2017

SURGICAL PATHOLOGY REPORT

Disordered Proliferative Phase, D&C.

DIAGNOSIS

DISORDERED PROLIFERATIVE PHASE.



SPECIMEN

D&C.

GROSS

i) Received multiple greyish white tissue pieces.

Microscopy

- i) Section examined shows small endometrial glands having columnar lining epithelium with round to oval nucleus with vacuoles.
- ii) Stroma shows mononuclear inflammatory cells.

Note : All biopsy specimen will be stored for 15 (fifteen) days, block and slides for 5 (five) years only from the time of receipt at the laboratory. No request, for any of the above, will be entertained after the due date.

Reference

- i) Rosai and Ackerman's Surgical Pathology.
- ii) Modern Surgical Pathology.

Gulshan Yadav, MD
Consultant Pathologist