

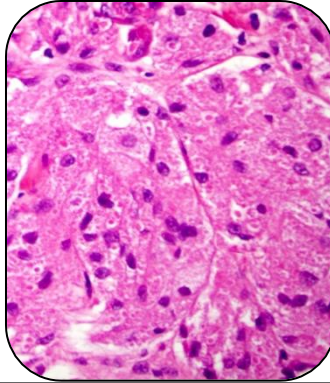
Patient Name	MRS. SEEMA	Client Name	Agarwal Pathology, Agra	Specimen Received	13/02/2017
Age/Sex	32/F	Client Code	MOLQ1420CM	Specimen Type	Tissue
Patient ID	011702130227	Ref. Doctor		Collection Date	16/02/2017
Specimen ID	MOLQ/B-101/17			Report Date	19/02/2017

SURGICAL PATHOLOGY REPORT

Benign Breast Lesion(Fibroadenoma), Right Breast.

DIAGNOSIS

BENIGN BREAST LESION(FIBROADENOMA).



SPECIMEN

Right Breast.

GROSS

- i) Received multiple greyish white two tissue pieces 4x2cm and 3x2cm.

Microscopy

- i) Section examined shows large number of ducts having cuboidal lining epithelium with small round nucleus with mycoepithelial cell and large number of fibrocollagenous Stroma.

Note : All biopsy specimen will be stored for 15 (fifteen)days, block and slides for 5(five) years only from the time of receipt at the laboratory. No request ,for any of the above ,will be entertained after the due date.

Reference

- i) Rosai and Ackerman's Surgical Pathology.
ii) Modern Surgical Pathology.

Gulshan Yadav, MD
Consultant Pathologist