

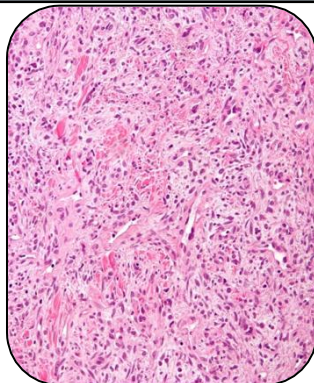
| | | | | | |
|---------------------|---------------|--------------------|----------------|--------------------------|------------|
| Patient Name | MR. DEEPAK | Client Name | Ghosh Path Lab | Specimen Received | 15/02/2017 |
| Age/Sex | 17/M | Client Code | MOLQ1123CM | Specimen Type | Tissue |
| Patient ID | 011702150166 | Ref. Doctor | | Collection Date | 15/02/2017 |
| Specimen ID | MOLQ/B-105/17 | | | Report Date | 18/02/2017 |

SURGICAL PATHOLOGY REPORT

Benign mesenchymal lesion, Cyst.

DIAGNOSIS

BENIGN MESENCHYMAL LESION.



SPECIMEN

Cyst.

GROSS

i) Received 5x2.5cm cyst. Cut section shows necrotic material.

Microscopy

- 1) Section examined shows squamous epithelial cells, small blood vessels fibrocollagenous tissue.
- 2) Section also shows nerve bundles.
- 3) No granuloma and no malignant cells seen .

Note : All biopsy specimen will be stored for 15 (fifteen)days, block and slides for 5(five) years only from the time of receipt at the laboratory. No request ,for any of the above ,will be entertained after the due date.

Reference

- i) Rosai and Ackerman's Surgical Pathology.
- ii) Modern Surgical Pathology.

Gulshan Yadav, MD
Consultant Pathologist