

Patient Name	MR. HARI SINGH	Client Name	Ghosh Path Lab	Specimen Received	09/02/2017
Age/Sex	55/M	Client Code	MOLQ1123CM	Specimen Type	Tissue
Patient ID	011702100080	Ref. Doctor		Collection Date	09/02/2017
Specimen ID	MOLQ/B-95/17			Report Date	17/02/2017

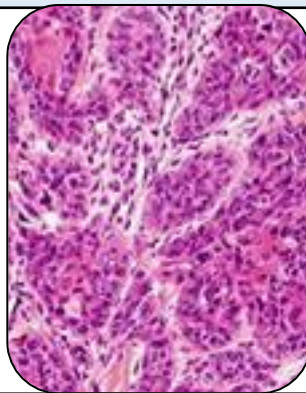
SURGICAL PATHOLOGY REPORT

Well to moderately differentiated squamous cell carcinoma, Swelling Heel.

DIAGNOSIS

WELL TO MODERATELY DIFFERENTIATED SQUAMOUS CELL CARCINOMA.

ADVICE- IHC(CYTOKERATIN).



SPECIMEN

Swelling Heel

GROSS

i) Received 10x10cm greyish white tissue piece with 6x6.5cm ulcer.

Microscopy

- 1) Section examined shows Squamous lining epithelium with marked hyperkeratosis with round to oval nucleus.
- 2) Squamous cells also shows large atypical vasicular nucleus with Anisonucleosis and keratin pearls.
- 3) Deeper tissue shows fibrocollagenous tissue with heavy mononuclear inflammatory cells.

Note : All biopsy specimen will be stored for 15 (fifteen)days, block and slides for 5(five) years only from the time of receipt at the laboratory. No request ,for any of the above ,will be entertained after the due date.

Reference

- i) Rosai and Ackerman's Surgical Pathology.
- ii) Modern Surgical Pathology.

Gulshan Yadav, MD
Consultant Pathologist

Report generated at MolQ Laboratory, Gurgaon