

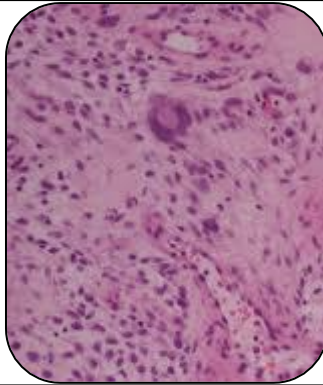
Patient Name	MRS. DARSHANA DEVI	Client Name	MolQ Collection Centre,	Specimen Received	08/02/2017
Age/Sex	40/F		UNA	Specimen Type	Tissue
Patient ID	011702080145	Client Code	MOLQ1192P	Collection Date	08/02/2017
Specimen ID	MOLQ/B-91/17	Ref. Doctor	K. C.LAB	Report Date	16/02/2017

SURGICAL PATHOLOGY REPORT

Skin tag with Hemorrhoids, External Haemorrhoid.

DIAGNOSIS

SKIN TAG WITH HEMORRHOIDS.



SPECIMEN

External Haemorrhoid.

GROSS

Received 1x1cm three greyish white tissue pieces.

Microscopy

- I) Section examined shows Squamous lining epithelium having small round nucleus.
- II) Dermis shows fibrocollagenous tissue and blood vessels.
- III) No granuloma and no malignant cells seen.

Note : All biopsy specimen will be stored for 15 (fifteen)days, block and slides for 5(five) years only from the time of receipt at the laboratory. No request ,for any of the above ,will be entertained after the due date.

Reference

- i) Rosai and Ackerman's Surgical Pathology.
- ii) Modern Surgical Pathology.

Gulshan Yadav, MD
Consultant Pathologist