

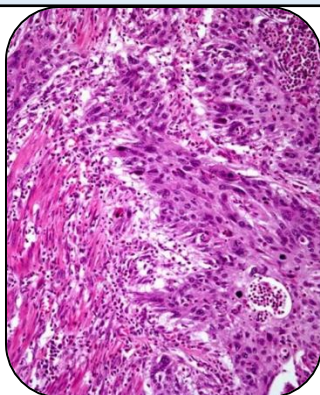
<b>Patient Name</b>	MR. ROHTASH	<b>Client Name</b>	Kriti Hospital	<b>Specimen Received</b>	06/02/2017
<b>Age/Sex</b>	50/M	<b>Client Code</b>	MOLQ1112CM	<b>Specimen Type</b>	Tissue
<b>Patient ID</b>	011702060232	<b>Ref. Doctor</b>	DR. NAVEEN SHAHG	<b>Collection Date</b>	06/02/2017
<b>Specimen ID</b>	MOLQ/B-89/17			<b>Report Date</b>	13/02/2017

## SURGICAL PATHOLOGY REPORT

### Keratogenous Cyst , Cystic Swelling Right Foot.

#### DIAGNOSIS

**KERATIGENOUS CYST.**



#### SPECIMEN

Cystic Swelling Right Foot.

#### GROSS

- 1) Received 1x2cm greyish white tissue piece.
- 2) Cut section shows cheesy necrotic material.

#### Microscopy

- i) Section examined shows keratin flakes ,small blood vessels, fibrocollagenous tissue squamous epithelial lining having small round nucleus.
- ii) No granuloma and no malignant cells seen.

**Note :** All biopsy specimen will be stored for 15 (fifteen)days, block and slides for 5(five) years only from the time of receipt at the laboratory. No request ,for any of the above ,will be entertained after the due date.

#### Reference

- i) Rosai and Ackerman's Surgical Pathology.
- ii) Modern Surgical Pathology.

**Gulshan Yadav, MD**  
Consultant Pathologist