

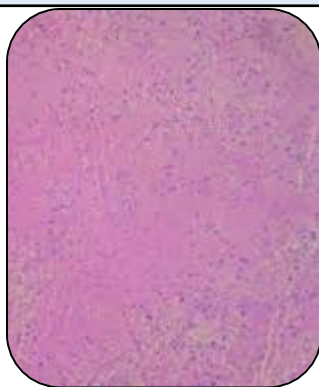
<b>Patient Name</b>	MR. DHARMENDER	<b>Client Name</b>	Multispeciality Hospital- Gurgaon	<b>Specimen Received</b>	27/01/2017
<b>Age/Sex</b>	48/M	<b>Client Code</b>	MOLQ1269P	<b>Specimen Type</b>	Tissue
<b>Patient ID</b>	011701270131	<b>Ref. Doctor</b>		<b>Collection Date</b>	27/01/2017
<b>Specimen ID</b>	MOLQ/B-63/17			<b>Report Date</b>	04/02/2017

## SURGICAL PATHOLOGY REPORT

### Acute Appendicitis, Appendix.

#### DIAGNOSIS

**ACUTE APPENDICITIS.**



#### SPECIMEN

Appendix.

#### GROSS

- i) Received 6x1.2cm long appendix.
- ii) Cut section shows fecolith.

#### Microscopy

- 1) Section examined shows lymphoid follicles with ulcerated mucosa.
- 2) Deeper tissue shows inflammatory infiltrate.

**Note :** All biopsy specimen will be stored for 15 (fifteen)days, block and slides for 5(five) years only from the time of receipt at the laboratory. No request ,for any of the above ,will be entertained after the due date.

#### Reference

- i) Rosai and Ackerman's Surgical Pathology.
- ii) Modern Surgical Pathology.

**Gulshan Yadav, MD**  
Consultant Pathologist