

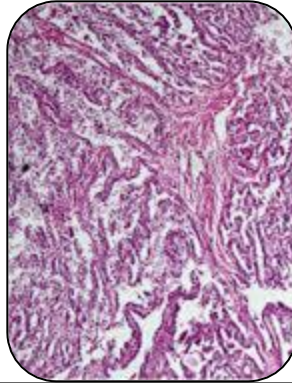
Patient Name	MRS. MEGHA	Client Name	Advanta Super Speciality Hospital (Rohtak)	Specimen Received	18/01/2017
Age/Sex	29/F	Client Code	MOLQ1299CM	Specimen Type	Tissue
Patient ID	011701180164	Ref. Doctor		Collection Date	18/01/2017
Specimen ID	MOLQ/B-38/17			Report Date	21/01/2017

SURGICAL PATHOLOGY REPORT

Tubal ectopic pregnancy, Left Fallopian Tube.

DIAGNOSIS

TUBAL ECTOPIC PREGNANCY.



SPECIMEN

Left Fallopian Tube.

GROSS

- i) Received 4x1cm fallopian tube.
- ii) Section shows tiny clot.

Microscopy

- 1) Section examined shows tubal lining epithelium with large number of RBC in the lumen (Blood clot).
- 2) No trophoblastic cells or villi seen.

Note : All biopsy specimen will be stored for 15 (fifteen) days, block and slides for 5 (five) years only from the time of receipt at the laboratory. No request, for any of the above, will be entertained after the due date.

Reference

- i) Rosai and Ackerman's Surgical Pathology.
- ii) Modern Surgical Pathology.

Gulshan Yadav, MD
Consultant Pathologist