

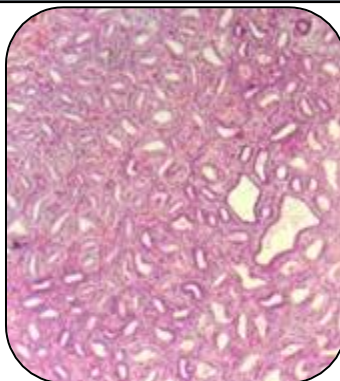
Patient Name	MRS. SANJU	Client Name	MolQ Collection Centre	Specimen Received	14/01/2017
Age/Sex	33/F		NRR	Specimen Type	Tissue
Patient ID	021701140001	Client Code	MOLQ1251CC	Collection Date	14/01/2017
Specimen ID	MOLQ/B-26/17	Ref. Doctor	DR. SHASHI PRATEEK	Report Date	18/01/2017

SURGICAL PATHOLOGY REPORT

Disordered proliferative phase, Endometrial Biopsy.

DIAGNOSIS

DISORDERED PROLIFERATIVE PHASE.



SPECIMEN

Endometrium Biopsy.

GROSS

i) Received multiple greyish white tissue pieces.

Microscopy

- i) Scanty Cellularity Section examined shows only few tortuous endometrial glands having cuboidal to columnar lining epithelium with small round nucleus and vacuoles.
- ii) Stroma shows mononuclear inflammatory cells and fibrin.
- iii) No granuloma and no malignant cell seen.

Note : All biopsy specimen will be stored for 15 (fifteen)days, block and slides for 5(five) years only from the time of receipt at the laboratory. No request ,for any of the above ,will be entertained after the due date.

Reference

- i) Rosai and Ackerman's Surgical Pathology.
- ii) Modern Surgical Pathology.

Gulshan Yadav, MD
Consultant Pathologist

Report generated at MolQ Laboratory, Gurgaon